

Review Article

Envenomations caused by fish in Brazil: an evolutionary, morphological, and clinical vision of a neglected problem

Vidal Haddad Junior^[1]  and Mônica Lopes-Ferreira^[2] 

[1]. Universidade Estadual Paulista, Faculdade de Medicina de Botucatu, Botucatu, SP, Brasil.

[2]. Laboratório Especial de Toxinologia Aplicada do Instituto Butantan, São Paulo, SP, Brasil.

ABSTRACT

Venomous fish are commonly found in Brazilian waters. The most important marine venomous fish species are stingrays (Dasyatidae, Gimnuridae, Myliobatidae, and Rhinopteridae families), catfish (Ariidae family), scorpionfish and lionfish (both Scorpaenidae family), and toadfish (Batrachoididae family). Meanwhile, Potamotrygonidae stingrays and Pimelodidae catfish are the most important venomous freshwater fish. The mechanisms of envenomation vary and involve various venomous apparatuses and glands. Despite not being highly developed, these venomous apparatuses in fish appear rudimentary, using structures such as fins and rays to inoculate toxins and rarely presenting with specialized structures. Toxins are produced by glandular tissue made up of proteinaceous cells, lacking true glands, and are positioned along the inoculation structures. However, systemic manifestations are rare. No antivenom serum has been developed for any species of American venomous fish. Brazilian venomous fish and their venoms have only recently attracted attention, leading to new studies not only addressing clinical issues in humans, but also exploring the discovery of new active substances with immense pharmacological potential.

Keywords: Bites and stings. Venomous animals. Stingrays. Scorpionfish. Toadfish. Catfish.

INTRODUCTION

Venomous fish have glandular structures that produce toxins and an apparatus capable of inoculating these toxins, such as fin spines, bony stingers, body spines, or teeth. Marine stingrays and catfish are examples of venomous fish. In contrast, poisonous fish can produce or store toxins that accumulate in body tissues such as the skin, liver, reproductive system, or muscles, and are incapable of active inoculation. Pufferfish are an example of this passive type of defense.

Venomous fish are commonly found in Brazilian waters. The most important marine families are Dasyatidae, Gimnuridae, Myliobatidae, and Rhinopteridae (marine stingrays), Ariidae (marine catfish), Scorpaenidae (scorpionfish and lionfish), and

Batrachoididae (toadfish). In freshwater environments, catfish (Pimelodidae) and stingrays (Potamotrygonidae) are the main species causing envenomations¹⁻⁷. Envenomation mechanisms vary between species; they involve various apparatuses and venomous glandular tissues, thereby posing distinct risks and lacking uniform preventive measures. Fish can have venom in different locations such as fin spines, caudal stingers, and spines in the preopercular or dorsal area, which are linked to venom glands¹⁻⁷.

EVOLUTION OF FISH VENOM

Fish skin has many important functions, including protection of internal structures, protection against infections and other diseases, and hydric balance⁸. It is composed of a layer of squamous cells and presents with other cells such as goblet cells (secretory cells

Corresponding author: Vidal Haddad Junior. **e-mail:** vidal.haddad-junior@unesp.br

Authors' contribution: The authors (VHJ and MLP) contributed equally to the preparation and adequacy of this manuscript.

Conflict of Interest: There are no conflict of interest in this manuscript.

Received 5 April 2023 • **Accepted** 20 June 2023

responsible for the cuticle), eosinophilic square-shaped cells, leukocytes, and macrophages. The cuticle is the external layer of mucous that reduces turbulence during swimming and protects against infections, as it contains antibodies^{8,9}.

In fish, there are two types of epidermal secretory cells: goblet cells and their secretions play a vital role in reducing turbulence and constitute the main component of the skin covering. Goblet cells discharge their secretions onto the surface through small canals⁹. Proteinaceous cells are the other secretor cells in fish skin⁹. They are responsible for toxin production and cannot discharge their content onto the skin surface, requiring a cutaneous lesion for it to occur. The main lineage of proteinaceous cells is clavate cells^{1,8,9}.

Crinotoxins are produced by proteinaceous cells in the skin and are released into the water or upon occurrence of skin lesions. They are not associated with venom apparatuses. Fish species that possess crinotoxins can be lethal to other fish in the same aquarium, and some crinotoxins are toxic to vertebrates^{1,9}.

Crinotoxins are an important defense mechanism in fish that produce them. Many fish species, such as eels, Moray eels, pufferfish, soapfish, scorpionfish and catfish^{1,8,9}, can produce crinotoxins in their epidermal proteinaceous cells. The primary function of crinotoxins is to protect against other organisms, such as bacteria, fungi, invertebrates and predators^{1,9}.

In some fish species, the thickening of the epidermis accompanied by an increased number of proteinaceous cells and toxins near and beside sharp and harmful structures (for example, fin spines or stingers), has increased the effectiveness of defense mechanisms and the toxin inoculation system. This adaptation provides obvious advantages for venomous fish within their

environment. Consequently, crinotoxins are called venoms and the adapted inoculation structures, venom apparatuses^{1,8,9}.

MATERIALS AND METHODS

The author has compiled information from previously published and peer-reviewed studies to describe and compare Brazilian marine and freshwater fish and their venomous apparatuses. The focus is on highlighting differences in inoculation systems and the severity of envenomations, in addition to demonstrating the clinical similarities manifested in patients affected by different toxins. The discussion also encompasses first-aid measures, taking into account the specific characteristics of each envenomation.

BRAZILIAN VENOMOUS FISH

MARINE FISH

A) Stingrays: Gimnuridae, Myliobatidae, Rhinopterae and Dasyatidae families.

Marine stingrays are a type of cartilaginous fish characterized by the presence of one to four bone-like stingers positioned in the caudal region and made of vasodentine (**Figure 1**). Stingrays are benthic fish, and injuries are common when a victim steps on the animal, which whips its tail as a defense mechanism. This can result in deep penetration of the stingers, which can reach 20 cm in length in some stingray species. However, in Brazil, injuries caused by stingrays primarily affect professional fishermen, for example when separating fish and shrimp in nets or when removing hooks. Meanwhile, stingray injuries are rare among bathers. The occurrence of local tissue trauma is important, as it leads to the disruption of the epithelial sheath, allowing the venom, present in the grooves of the stinger as a thick glandular mass, to flow into the wound^{1-7,10,11}.

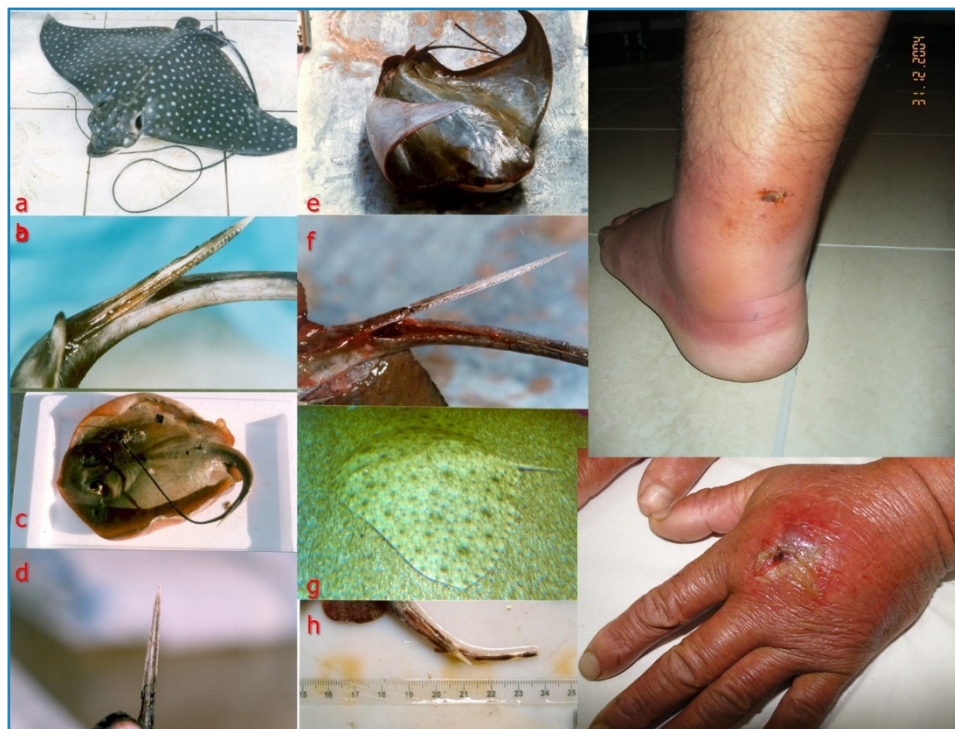

FIGURE 1: Left: **a.** *Aetobatus narinari*, the spotted stingray; **b.** Stinger of the spotted stingray; **c.** *Hypanus* sp., the sandpaper or nail stingray; **d.** Stinger of *Hypanus* stingray. Central images: **e.** *Rhinoptera bonasus*, the cownose stingray; **f.** Stinger of the cownose stingray; **g.** *Gimnura* sp., the butterfly or butter stingray and **h.** Stinger of *Gimnura* stingray. Right: envenomations caused by marine stingrays. **Photos:** Vidal Haddad Junior

The size and effectiveness of stingers in promoting envenomation vary among the stingray families found in Brazilian waters. The Gimnuridae family (butterfly or butter stingrays, arraia-manteiga, or borboleta) has a small stinger near the base of the tail; envenomations are rare and generally not as serious as the whip movement, as it does not allow a violent blow, thus minimizing trauma and venom inoculation capacity (Figure 1). Other families, especially Dasyatidae (nail or sandpaper stingrays, arraia-prego, or arraia-lixia (Figure 1) have more developed stingers located in the medial or distal portion of the tail, which can cause severe injuries and serious victim envenoming. The main stingray species capable of severe envenomation in Brazil are *Hypanus* (formerly *Dasyatis*) *guttata*, *H. say*, and *H. americana* (the first being the major cause of envenomations), *Rhinoptera bonasus* (cownose stingray or ticonha stingray), and *Aetobatus narinari*, the spotted stingray or arraia-pintada (Figure 1).

Envenomation from marine stingrays is severe, leading to intense pain, local edema, erythema, and systemic manifestations associated with pain, such as malaise and cold sweats. Cutaneous necrosis is not rare, but not as common as in envenomations by freshwater stingrays^{1-7,11}. If necrosis becomes established, the result can be chronic ulcers that remain for months, significantly impairing the activities of the affected individual¹¹. (Figure 1)

B) Marine Catfish: the Ariidae family

Catfish are the most frequent fish associated with human injuries in both marine and freshwater environments, and the Ariidae family is the most representative on the Brazilian Coast (Figure 2)^{1-7,12}. The *Genidens* genus (*Genidens genidens*, urutu catfish), *Cathorops* (*Cathorops agassizii*, yellow catfish), and *Bagre* (*Bagre bagre*, *Bagre marinus*, flag catfish) are associated with most injuries in the South Atlantic Ocean^{1-7,12}. Envenomation occurs

when fishermen handle fish and shrimp in their nets or when swimmers step on small fish discarded on the beach by amateur or professional fishermen¹¹.

Marine catfish cause injuries through serrated bony stingers located anterior to the dorsal and pectoral fins, which can be locked in an extended position, increasing the risk of severe injuries (Figure 2). The stingers of catfish are covered by an integumentary sheath containing glandular venomous tissue. Upon penetration of the stinger into the victim, this epithelium is disrupted, leading to the release of venom into the wound. The victim of a catfish injury suffers intense pain, blanching at the puncture site, malaise, vomiting, and has the possibility of developing local skin necrosis^{1-7,12} (Figure 2). Envenomation is primarily localized and considered moderately serious, without compromising internal organs. However, it can result in several days of work incapacity and potential complications, such as the retention of broken stinger fragments and severe bacterial infections¹².

C) Scorpionfish and Lionfish: the Scorpaenidae family

The stonefish, belonging to the genus *Synanceia* (Synanceiidae family), is renowned as the most venomous fish globally, exclusively inhabiting the Indo-Pacific marine waters. Envenomation caused by these fish results in severe consequences, with numerous reported fatalities attributed to their stings. Envenomations caused by fish from the Atlantic Ocean, in contrast, rarely result in deaths, with reported fatalities usually being associated with subsequent infections¹⁻⁷. The Scorpaenidae family includes highly dangerous venomous fish species, such as *Pterois* sp. (lionfish) and *Scorpaena* sp. (true scorpionfish)^{1-7,13}. *Scorpaena* are common in the coastal waters of the country and lionfish, after dissemination in the Atlantic Ocean, are now present in Brazilian waters, especially in the North and Northeast regions of Brazil^{14,15}.



FIGURE 2: Right: *Bagre* sp. (the flag catfish), *Cathorops agassizii* (the yellow catfish) and details of the pectoral and dorsal stingers. Right: injuries caused by marine catfish in bathers. Photos: Vidal Haddad Junior.

Scorpionfish are the most venomous Brazilian fish, causing serious envenomation in amateur and professional fishermen¹². The black scorpionfish (*Scorpaena plumieri*) and red scorpion fish (*Scorpaena brasiliensis*), popularly called beatriz, mangangá, or mamangava, are the most common fish in the genus *Scorpaena* associated with injuries in humans¹³ (Figure 3).

Lionfish are currently widespread in the Atlantic Ocean, including regions such as the USA, Caribbean and South America, including Brazil¹⁵. Originally native to the Indian and Pacific Oceans, this fish not only poses a significant risk of severe envenomation but also represents an ecological threat in the invaded areas. Lionfish act as predators to local fauna and lack natural predators that can effectively control their population^{14,15}. (Figure 3)

The venom apparatus of this family is composed of 12-13 spines in the dorsal fin, three spines in the anal fin, and two pelvic spines (Figure 3). The Brazilian scorpionfish has 12 spines in the dorsal fin, with venomous glandular tissue in the grooves of the upper two-thirds of each spine. Similar to catfish envenomation, the venom is released into the wound when the sting penetrates the skin of the victim, and the epithelium is broken¹.

Scorpionfish envenomation is severe and causes intense excruciating pain. Moderate edema is observed at the puncture(s) site (Figure 3), and the resulting signs and symptoms are systemic, distinct from those seen in other Brazilian venomous fish^{1-7,13}. Symptoms such as malaise, fever, local adenopathy, respiratory and cardiac alterations, hallucinations, and seizures may be observed¹³. In a series of 23 injuries, all patients presented with intense pain and systemic alterations, confirming the severity of the envenomation¹³.

D) Toadfish: Batrachoididae Family

In Brazil, the family Batrachoididae comprises various fish

species; however, the genus *Thalassophryne* is primarily responsible for human injuries. Among the *Thalassophryne nattereri* species, niquin, miquim, and toadfish are most commonly associated with envenomation in the North and Northeast regions^{1-7,16-18} (Figure 4). These fish remain motionless in sandy or muddy bottoms and are numerous in estuarine areas, causing injuries when stepped on by fishermen and bathers in shallow waters.

The *Thalassophryne* genus toadfish has the most sophisticated venom apparatus known in fish^{1-7,16-18}. The venom is inoculated through a system of two dorsal and two preoperative hollow spines when a basal and well-constituted unique gland is pressured, and it deeply injects content into the victim (Figure 4). Toadfish envenomation causes intense pain, local erythema, edema, and cutaneous necrosis (Figure 4). It does not cause systemic manifestations beyond those associated with the pain process¹⁶⁻¹⁸.

FRESHWATER FISH

Freshwater stingrays: Potamotrygonidae family

Elasmobranches of the Potamotrygonidae family live only in the freshwater environments of South America. There are three genera of South American freshwater stingrays, the most important in terms of the number of species associated with human envenomation is the *Potamotrygon* genus. In the Amazon region, *Potamotrygon orbyigni*, *Potamotrygon scobina* and *Potamotrygon motoro* species are most commonly associated with injuries, whereas in the Paraná/Paraguay River system, *Potamotrygon motoro* and *Potamotrygon falkneri* cause the most envenomations^{1-7,11,19-22} (Figure 5).

Freshwater stingrays are currently spreading throughout the Brazilian freshwater system and are found in the entire Amazon region and Paraná/Paraguay River system. Recently, the species




FIGURE 3: *Thalassophryne* sp., the niquin toadfish, and details of the dorsal and pre-opercular glands and hollow spines. **Right:** a typical envenomation with double perforation of the toe of the victim. **Photos:** Vidal Haddad Junior.

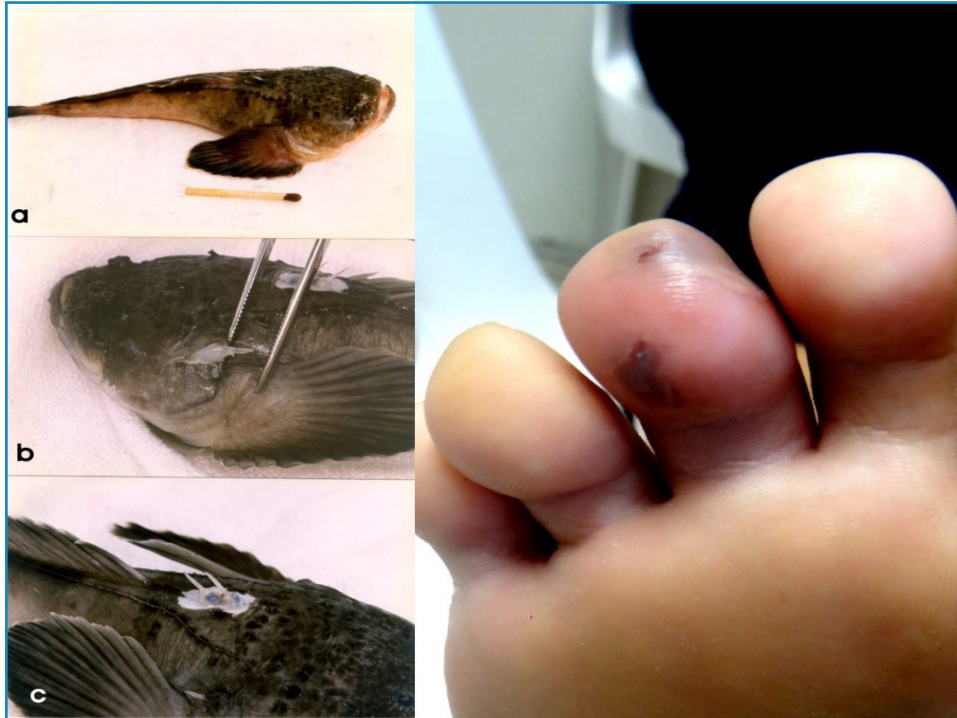

FIGURE 4: Left: Scorpionfish (*Scorpaena plumieri*) and its venom apparatus. Central: Lionfish (*Pterois volitans*) and venom apparatus. Right: envenomations caused by scorpionfish (the last was provoked by a lionfish). Photos: Vidal Haddad Junior.

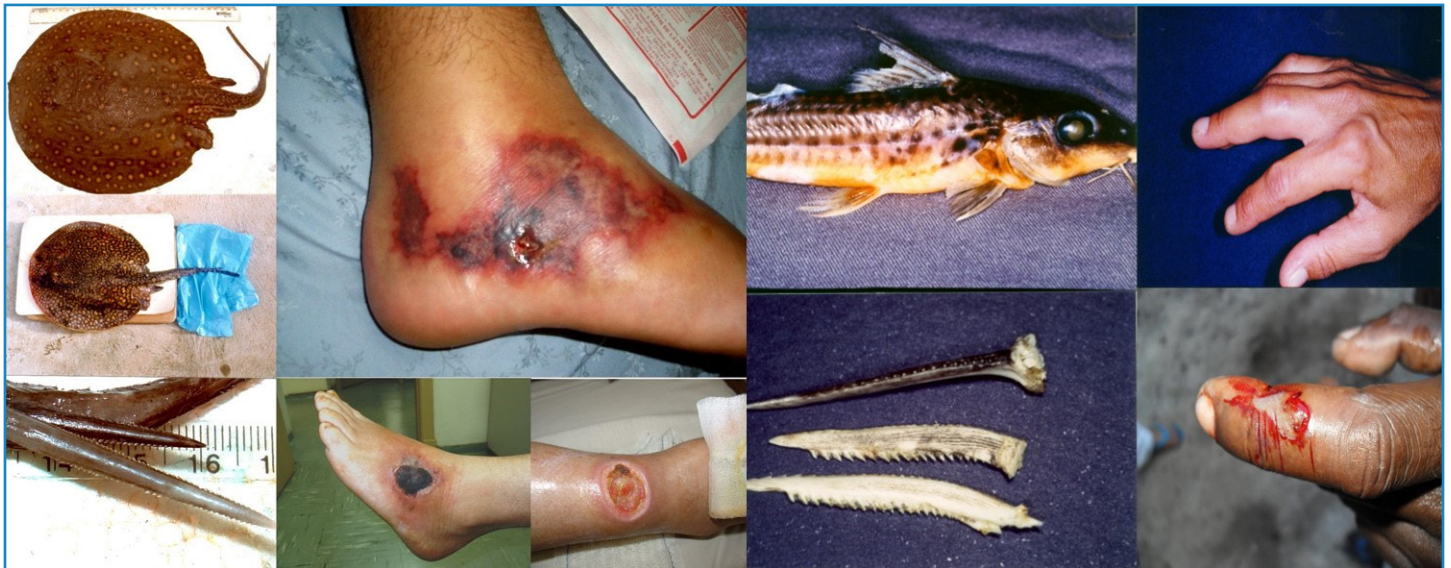

FIGURE 5: Left: Freshwater stingrays (*P. motoro amandae* and *P. falkneri*), the stingers in the tail and envenomations showing skin necrosis and ulcers. Right: freshwater catfish (*Pimelodus maculatus*), stingers in dorsal and pectoral positions and envenomations/trauma caused by these fish. Photos: Vidal Haddad Junior.

Potamotrygon motoro amandae and *Potamotrygon falkneri* have been reported in the Tietê River, in São Paulo State, where they have not been previously described²².

Freshwater stingrays, like marine stingrays, have one or more caudally located vasodentine stings, a substance with a bony consistency. The stings are serrated and can cause serious lacerations in the victim (Figure 5). To aggravate this situation, in contrast to most marine stingray tails, the stings in freshwater

stingrays are situated in a medial or distal position on the tail, which is thick and muscular. As a result, the whip action generated by these stingrays is highly powerful, leading to deep sting penetration and inoculation of the venom. Consequently, trauma occurs due to tissue destruction and envenomation^{1-6,11,22}.

The risk of injuries caused by freshwater stingrays primarily affects riverside dwellers and tourists who cross small watercourses in continental waters and inadvertently step on the stingrays^{10,20}.

Freshwater stingrays also have a habit of half-burying themselves in the sand or mud, making it difficult for victims to spot them.

The clinical manifestations of injuries caused by freshwater stingrays are similar to those observed in injuries caused by marine stingrays, including excruciating pain, edema, erythema, and systemic phenomena associated with pain and agitation (Figure 5). Notably, cutaneous necrosis is more frequently observed in freshwater stingray envenomations, probably due to a higher level of proteolytic enzymes in the venom^{1-7,11,22,23}.

Freshwater catfish – Pimelodidae Family

Freshwater catfish belonging to the Siluriform order are commonly found in Brazilian rivers and lakes. The main genera associated with envenomation are *Pimelodus* and *Pimelodella* (bagres and mandis), with the species *Pimelodus maculatus*, known as mandijuba, being the main culprit. Mandijuba is a widely encountered fish with significant economic value. It often comes into contact with amateur and professional fishermen, the main victims of this kind of injury (Figure 5)¹⁷⁻²². Fish from the *Pimelodella* genus (mandi-chorão) can also cause painful stings, but due to their small size and lack of economic interest, the risk of injuries is smaller. While there are other species of freshwater catfish with venom in their stingers, they only cause sporadic injuries and are not of epidemiological importance^{1-7,24,25}.

Many fish in this family have bony spines anterior to the dorsal and pectoral fins, but only a few have venom. The venom is housed within an integumental sheath that envelops the stinger and is released into the wound when the sheath breaks upon penetration into the victim (Figure 5)^{20,24,25}. The structures and mechanisms of envenomation are very similar to those of the marine Ariidae catfish^{24,25}.

Sting penetration and venom inoculation cause intense pain, edema, and erythema. (Figure 5). The pain process is intense and fades after approximately 6 hours; however, complications are common, including sting-fragment retention and bacterial infections^{24,25}.

DISCUSSION AND CONCLUSIONS

When comparing venom systems between terrestrial and aquatic animals, it is generally observed that the venom apparatuses of snakes, spiders, and scorpions have evolved more than those in fish. While the venomous apparatus in fish appears to be rudimentary, it relies on sharp structures such as fin spines for toxin delivery and only rarely exhibits specialized structures like stingers. Venomous fish are common in Brazilian waters, yet there is limited knowledge regarding injuries caused by them in at-risk populations, including fishermen, tourists, riverside inhabitants, biology professionals, fish control workers, and breeders.

Systemic manifestations in injuries caused by fish are rarely observed, and this type of envenomation is not considered a priority within the Brazilian health system, unlike snakes, spiders, and scorpions²⁶. No anti-venom serum has been developed for any species of venomous fish in Brazil. It is important to note that morbidity (illness and incapacity without death) is significant in humans injured by venomous fish. This justifies the need for improvements and new studies on first-aid measures for victims. An envenomation from a stingray, for instance, can keep a patient away from work for months due to necrosis and subsequent bacterial infections.

While the composition of venom may vary, all venomous fish cause similar clinical manifestations, including intense pain, local edema, erythema, and possible cutaneous necrosis, as well as delayed complications such as bacterial or fungal infections in the wound. Severe systemic symptoms are mainly observed in envenomations caused by members of the Scorpaenidae family, which may even lead to fatality. Freshwater stingrays, on the other hand, are known to cause notable local sequelae, with intense inflammation and frequent extensive cutaneous necrosis¹⁻⁷.

The venom produced by fish is considered thermolabile, meaning it is sensitive to heat. Applying tolerable hot water to the affected member for 30-90 minutes improves the pain. Fish venom is really unstable at high temperatures and degrades with heat, which is the scientific basis for using the immersion of the wound in hot water. However, the pain returns after withdrawing the compromised member from immersion. The presence of extreme paleness in the area indicates intense vasoconstriction, which has been experimentally confirmed in catfish venoms. This vasoconstriction may also explain the main beneficial effect of immersion in hot water, which promotes immediate vasodilatation at the wound site¹⁻⁷.

It is crucial to refer victims to a hospital for wound cleansing and the extraction of any remaining sting or spine fragments left in the wound. Since severe envenomations are not so common, studies on Brazilian venomous fish and their venoms have only recently come into the spotlight. Further research is necessary, not only to investigate their clinical complications but also to explore the discovery of new active substances with immense pharmacological potential.

REFERENCES

1. Halstead BW. 1970. Poisonous and Venomous Marine Animals of the World (Vol 3, Vertebrates). Washington: US Government Print; 1970. 986p.
2. Haddad Jr V. Atlas de Animais Aquáticos Perigosos do Brasil: guia médico de identificação e tratamento (Atlas of Dangerous Aquatic Animals of Brazil: a medical guide of identification and treatment). São Paulo: Editora Roca; 2000. 145 p.
3. Haddad Jr V. Animais aquáticos de importância médica. Rev Soc Bras Med Trop. 2003;36(5):591-7.
4. Haddad Jr V. Animais Aquáticos Potencialmente Perigosos do Brasil: Guia Médico e Biológico. (Potentially Dangerous Aquatic Animals in Brazil Medical and Biological Guide.). São Paulo: Editora Roca; 2008. 288 p.
5. Haddad Jr V. Medical Emergencies Caused by Aquatic Animals: A Zoological and Clinical Guide. Switzerland: Springer Publishers; 2016. 112 p.
6. Haddad Jr V. Medical Emergencies Caused by Aquatic Animals: A Biological and Clinical Guide to Trauma and Envenomation Cases. Switzerland: Springer Publishers; 2021. 350 p.
7. Gopalakrishnakone P, Haddad Jr V. Marine and Freshwater Toxins. Switzerland: Springer Publishers; 2016. 476 p.
8. Quay WB. Integument and the environment: glandular composition, function, and evolution. American Zoologist. 1972;12(1):95-103.
9. Cameron AM, Endean R. Epidermal Secretion and the Evolution of Venom Glands in Fishes. Toxicon. 1973;11(5):401-10.
10. Haddad Jr V. Profile of skin diseases in a community of fishermen in the northern coast of the state of São Paulo: the expected and the unusual. An Bras Dermatol. 2019;94(1):24-8.

11. Haddad Jr V, Cardoso JLC, Garrone Neto D. Injuries by marine and freshwater stingrays: history, clinical aspects of the envenomations and current status of a neglected problem in Brazil. *J Venom Anim Toxins Incl Trop Dis*. 2013;19:16.
12. Haddad Jr V, Martins IA. Frequency and gravity of human envenomation caused by marine catfish (suborder Siluroidei): a clinical and epidemiological study. *Toxicon*. 2006;47(8):838-43.
13. Haddad Jr V, Martins IA, Makyama HM. Injuries caused by scorpionfishes (*Scorpaena plumieri* Bloch, 1789 and *Scorpaena brasiliensis* Cuvier, 1829) in the Southwestern Atlantic Ocean (Brazilian Coast): epidemiologic, clinic and therapeutic aspects of 23 stings in humans. *Toxicon*. 2003;42(1):79-83.
14. Haddad Jr V, Stolf HO, Risk JY, França FOS, Cardoso JLC. Report of 15 injuries caused by lionfish (*Pterois volitans*) in aquarists in Brazil: a critical assessment of the severity of envenomations. *J Venom Anim Toxins Incl Trop Dis*. 2015;21:8.
15. Haddad Jr V, Giarrizzo T, Soares MO. Lionfish envenomation on the Brazilian coast: first report. *Rev Soc Bras Med Trop*. 2022;55:e0241.
16. Lima LAF, Lopes-Ferreira M. Estudo clínico e experimental sobre o envenenamento causado pelo peixe *Thalassophryne nattereri* (niquim). *An Bras Dermatol*. 2000;75(4):435-43.
17. Haddad Jr V, Pardal PPO, Cardoso JLC, Martins IA. The venomous toadfish *Thalassophryne nattereri* (niquim or miquim): report of 43 injuries provoked in fishermen of Salinópolis (Pará State) and Aracaju (Sergipe State), Brazil. *Rev Inst Med Trop São Paulo*. 2003;45(4):221-3.
18. Haddad Jr V, Lopes-Ferreira M, Mendes AL. Hemorrhagic Blisters, Necrosis, and Cutaneous Ulcer after Envenomation by the Niquim Toadfish. *Am J Trop Med Hyg*. 2019;101(3):476-7.
19. Garrone Neto D, Cordeiro R, Haddad Jr V. Acidentes do trabalho em pescadores artesanais da região do Médio Rio Araguaia, Tocantins, Brasil. *Cad Saúde Pública*. 2005; 21(3):795-803.
20. Silva GC, Sabino J, Alho CJ, Nunes VL, Haddad Jr V. Injuries and envenoming by aquatic animals in fishermen of Coxim and Corumbá municipalities, State of Mato Grosso do Sul, Brazil: identification of the causative agents, clinical aspects and first aid measures. *Rev Soc Bras Med Trop*. 2010;43(5):486-90.
21. Haddad Jr V, Fávero Jr EL, Ribeiro FA, Ancheschi BC, Castro GI, Martins RC, et al. Trauma and envenoming caused by stingrays and other fish in a fishing community in Pontal do Paranapanema, state of São Paulo, Brazil: epidemiology, clinical aspects, and therapeutic and preventive measures. *Rev Soc Bras Med Trop*. 2012;45(2):238-42.
22. Haddad Jr V, Garrone Neto D, Barbaro KC, Paula Neto JB, Marques FPL. Freshwater stingrays: study of epidemiologic, clinic and therapeutic aspects based in 84 envenomings in human and some enzymatic activities of the venom. *Toxicon*. 2004;43(3):287-94.
23. Moreira ISR, Haddad Jr V. Mapping of the venomous stingrays of the *Potamotrygon* genus in the Tietê River, São Paulo State, Brazil. *Rev Soc Bras Med Trop*. 2022;55:e0216.
24. Haddad Jr V, Lastória JC. Acidentes por mandijubas (mandis-amarelos): aspectos clínicos e terapêuticos. *Diagnóstico & Tratamento*. 2005;10(3):132-3.
25. De Aquino GNR, De Souza CC, Haddad Jr V, Sabino J. Injuries caused by the venomous catfish pintado and cachara (*Pseudoplatystoma* genus) in fishermen of the Pantanal region in Brazil. *An Acad Bras Cienc*. 2016;88(3):1531-7.
26. Reckziegel GC, Dourado FS, Garrone Neto D, Haddad Jr V. Injuries caused by aquatic animals in Brazil: an analysis of the data present in the information system for notifiable diseases. *Rev Soc Bras Med Trop*. 2015;48(4):460-7.